



© 2004 British Editorial Society of Bone and Joint Surgery Volume 86-B(7), September 2004, pp 1065-1068

**A correction of windswept deformity by fixator assisted nailing: A REPORT OF TWO CASES**

[Case Report]

Eralp, L.; Kocaoglu, M.; Çakmak, M.; Özden, V. Emre

From the University of Istanbul, Istanbul, Turkey

L. Eralp, MD

M. Kocaoglu, MD

M. Çakmak, MD

V. Emre Özden, MD

University of Istanbul, Istanbul School of Medicine, Department of Orthopaedic Surgery and Traumatology, Capa-Topkapi, 34390 Istanbul, Turkey.

Correspondence should be sent to Dr L. Eralp.

Received 2 September 2003; Accepted after revision 9 December 2003

**Abstract**

We report two cases with windswept deformities of the lower extremities. All deformities were corrected by fixator-assisted intramedullary nailing. At the latest follow-up, the patients had normal alignment, without symptoms and no loss of correction.

---

'Wind swept deformity' describes a pathological valgus deformity in one knee in association with a varus deformity in the other. It usually develops secondary to metabolic bone diseases but exceptions have been described.<sup>1</sup>

Correction of the deformity by osteotomy is well-known. After osteotomy, stabilisation can be achieved either by internal fixation (K-wires, screws, plates or intramedullary nails) or external fixation (unilateral or circular or casting).<sup>2</sup>

In patients with metabolic bone diseases, limb deformities are usually multiapical (i.e. long bowing) and complex.<sup>3</sup> The poor bone quality in this group makes optimal correction and the control of the alignment difficult.

A new technique, fixator-assisted nailing (FAN), combines the accuracy, minimal invasiveness and safety of the Ilizarov principle, with patient compliance and the comfort of internal fixation in order to provide permanent protection of the correction.<sup>2</sup>

This study investigates the result of treatment of two cases with windswept deformity treated by FAN.

## Case reports

**Case 1.** A 24-year-old man complained of difficulty in walking and deformity of his legs. The deformity had deteriorated over the previous 12 years. Eighteen years before he had been treated for Vitamin D-resistant rickets.

Physical examination revealed right-side genu valgum and left-side genu varum (Fig. 1a). The range of movement of the knees was 0° to 145° without any ligamentous laxity or limb-length discrepancy. Radiographic assessment of the lower extremities by standing anteroposterior radiographs showed long bowing or multiapical and angular deformities of both femora and the left tibia (Fig. 1b). The pre-operative mechanical axis of deviation (MAD) was -44 mm on the right and + 90 mm on the left. On the right side, the mechanical lateral distal femoral angle (mLDFDA) and medial proximal tibial angle (MPTA) were 73° and 85° respectively. On the left, they were 105° and 75° respectively.



Fig. 1a

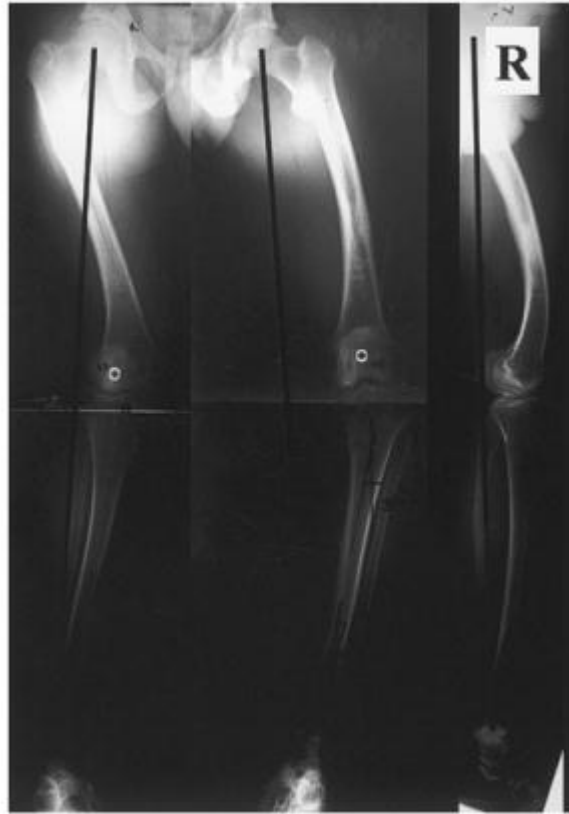

Fig. 1b

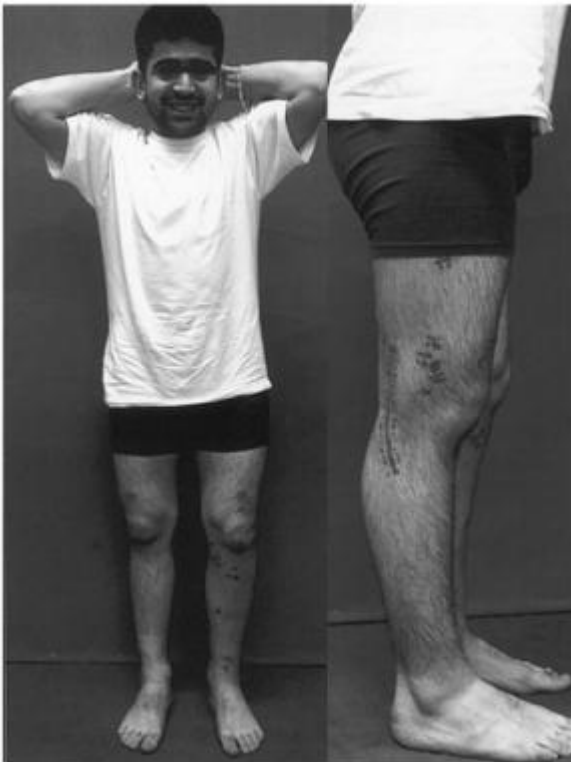

Fig. 1c

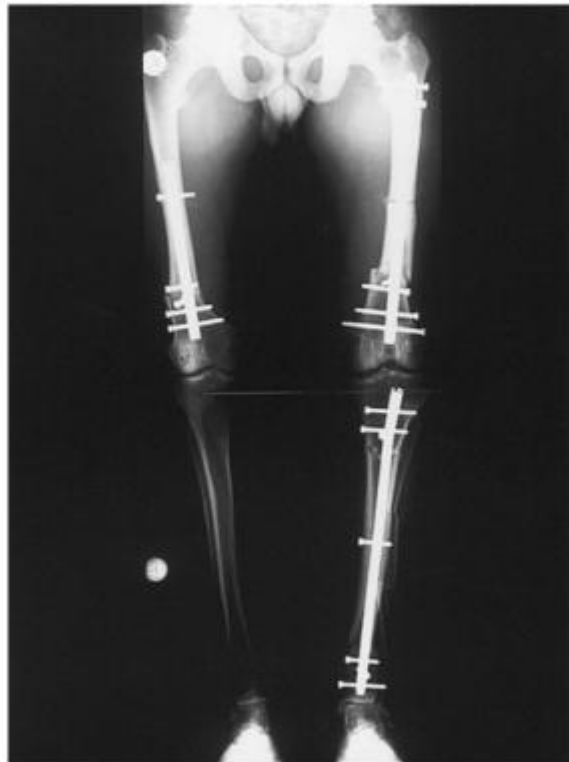

Fig. 1d

Fig. 1 Case 1, a 24-year-old man with windswept deformity of the lower

extremities a) pre-operative clinical view, b) pre-operative standing radiographs, c) post-operative clinical view at 24 months and d) post-operative standing radiograph at 24 months.

---

The deformities were corrected by a varus osteotomy of the femur on the valgus side and a valgus osteotomy of both femur and tibia on the varus side by FAN. The operation was performed on a radiolucent table. Initially, a prophylactic peroneal nerve release was performed on the valgus side. This procedure protects the nerve against stretching during an acute, bony varus correction. A unilateral external fixator (Hexfix, Smith & Nephew, Nashville, Tennessee) was used. The fixator is applied laterally on the femur and medially on the tibia, as described by Paley et al.<sup>3</sup> In order not to interfere with the intramedullary nail, the external fixation pins are inserted anteriorly in the distal femur and posteriorly in both the proximal and distal tibia. After application of the external fixator, a focal dome osteotomy is performed at predetermined levels by the multiple drill-hole technique. The fixator is adjusted to correct the deformity and intra-operative radiographs are taken. When the desired amount of correction is achieved, the external fixator is locked and intramedullary nailing is then undertaken. If satisfactory correction is not achieved, this is readjusted and further radiographs are taken. A retrograde femoral nail is used for the correction of all femoral deformities. This is performed percutaneously, without exposure of the knee joint.<sup>3</sup> The intramedullary canal is overreamed by 1 mm more than the diameter of the intramedullary nail which is to be used. The nail is then inserted. Distal, proximal and interfragmentary locking screws are inserted free-hand but under image intensifier control. When the medullary canal is considered too large for the nail, especially in the metaphyseal area, interference screws are inserted perpendicularly to the locking screws to narrow the medullary canal in both the frontal and sagittal planes.<sup>3</sup> The external fixator is removed after fixation. An epidural catheter is inserted for post-operative analgesia. On the day of the operation, isometric quadriceps exercises and ankle movements are encouraged. A Cryo-cuff (Aircast, Summit, New Jersey) is applied in order to reduce swelling in the knee. On the first post-operative day, knee movements and walking exercises with two sticks are commenced. The patient gradually discards their walking sticks during the first month.

At each visit the patient was assessed clinically and radiologically. The radiological parameters used for pre- and post-operative assessment have been previously described by Paley et al.<sup>4</sup> Pain, limping, walking ability, and range of movement of the knee, hip and ankle were recorded.

At the latest post-operative follow-up examination at 24 months (Fig. 1c) he had no pain or limp. The range of movement of both knees was 0° to 140°. For the ankles, dorsiflexion was 25° bilaterally and plantar flexion

was 40° on the right and 45° on the left. The post-operative MAD was 9 mm on the right and 10 mm on the left. On the right the mL DFA and MPTA were 87° and 85° respectively. On the left they were 90° and 86° respectively. Radiologically, there was complete bony consolidation (Fig. 1d).

**Case 2.** A 20-year-old woman, who had been treated for Vitamin-D-dependent rickets 17 years earlier presented with deformity of her legs and pain on walking.

Examination revealed right genu valgum and left genu varum (Fig. 2a). The range of movement of the right knee was -5° to 130° and 0° to 140° for the left knee. There was 7 mm shortening of the right leg. Radiographs showed multiapical angular deformities of both femora and tibiae (Fig. 2b). The pre-operative MAD was -112 mm on the right and +93 mm on the left. On the right side, the mL DFA and MPTA were 58° and 103° respectively. On the left they were 108° and 81° respectively. The operation was performed as described in case 1 and the post-operative follow-up was identical.

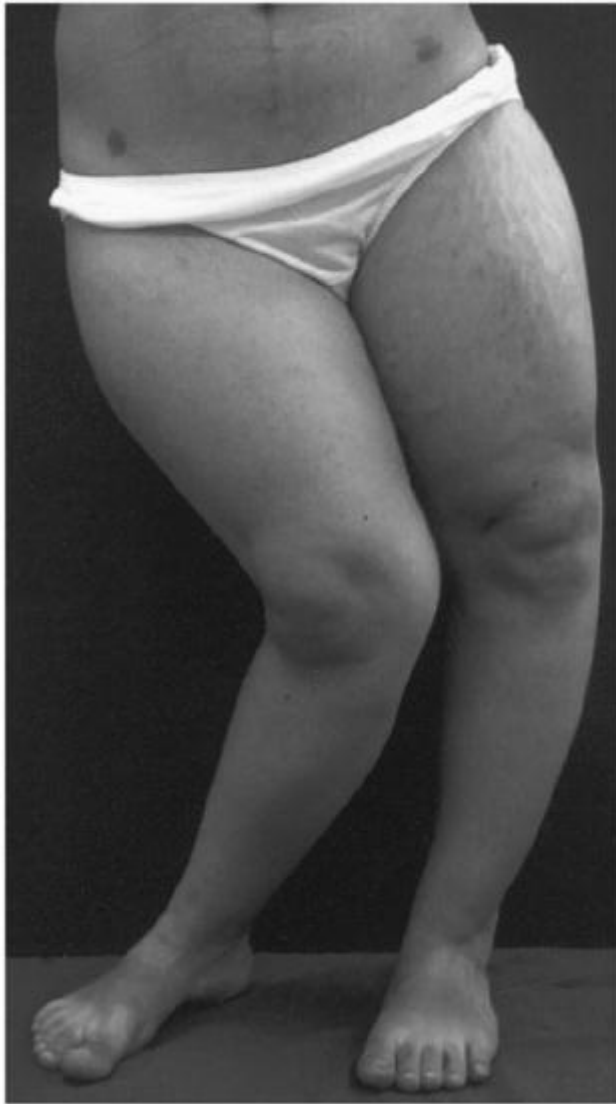

Fig. 2a

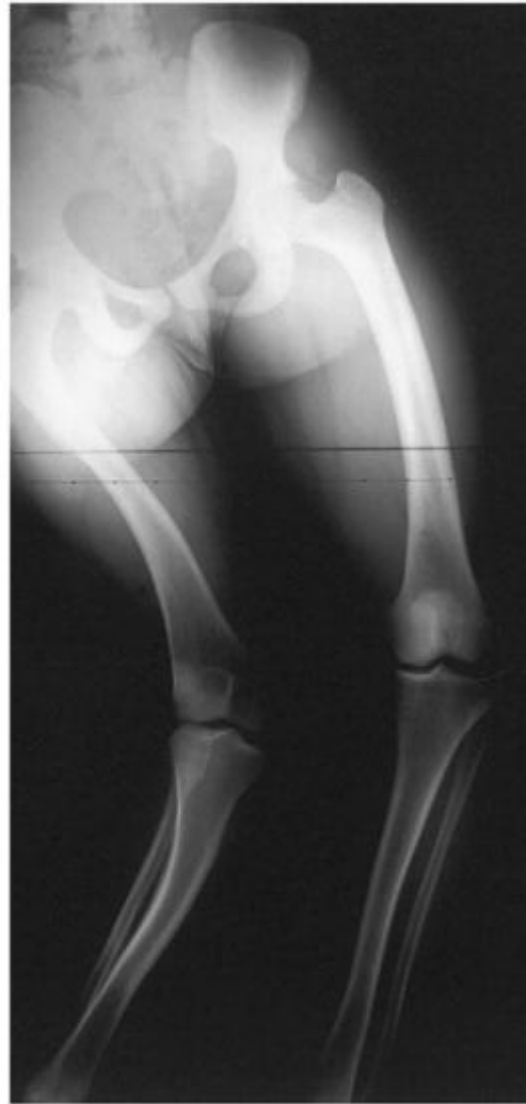

Fig. 2b

Fig. 2 Case 2, a 20-year-old woman with a windswept deformity of the lower extremities a) pre-operative clinical views and b) pre-operative standing radiograph.

---

At the latest follow-up examination, at 24 months (Fig. 3a), she had no pain or limp. The range of movement of her knees was  $0^{\circ}$  to  $140^{\circ}$  while dorsiflexion and plantar flexion of both ankles was  $30^{\circ}$  and  $35^{\circ}$  respectively. The post-operative MAD was +5 mm on the right and +11 mm on the left. On the right, the mLDFA and MPTA were  $86^{\circ}$  and  $90^{\circ}$ , respectively. On the left, they were  $87^{\circ}$  and  $85^{\circ}$  respectively. Radiologically, there was complete bony consolidation (Fig. 3b).

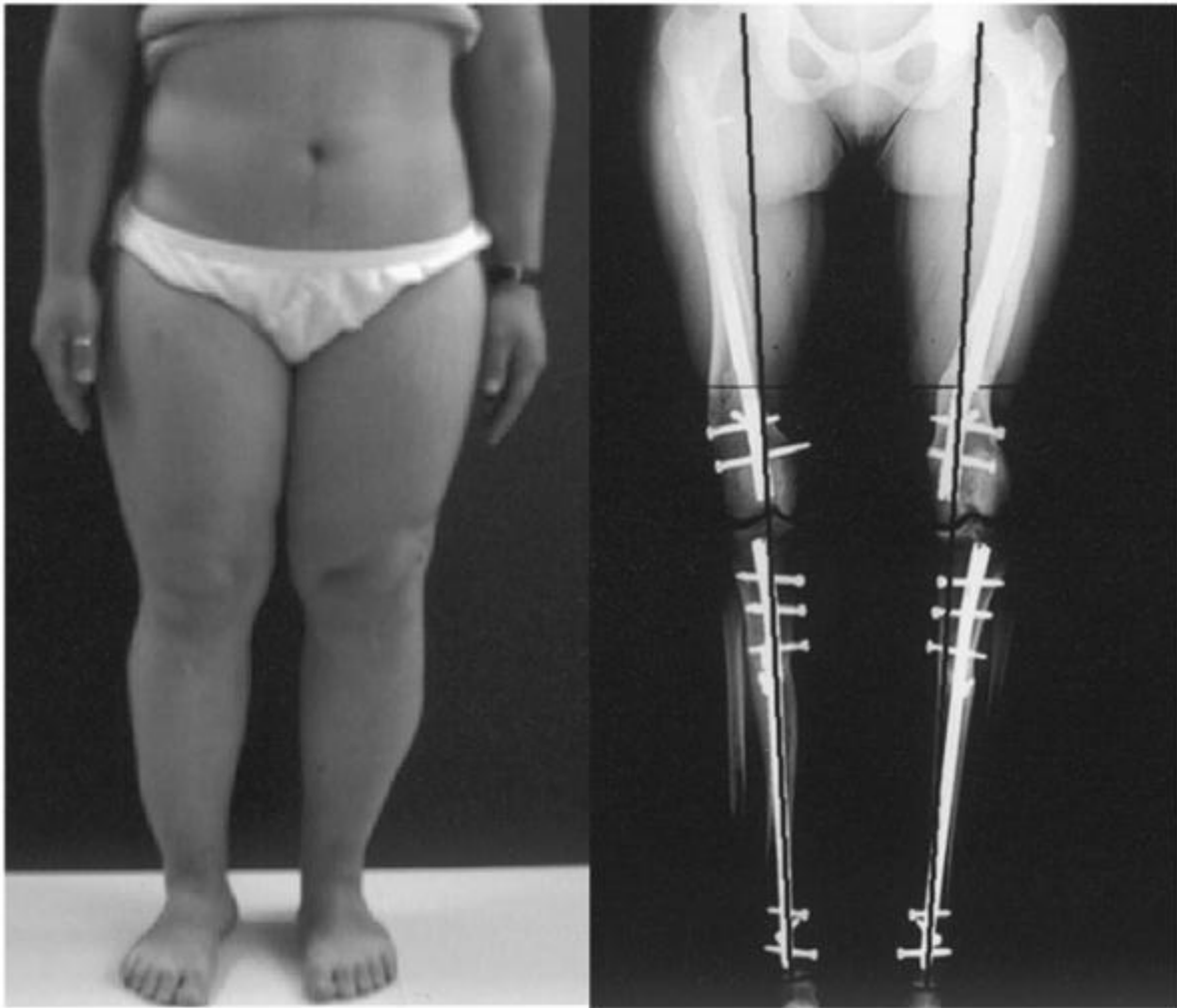


Fig. 3a

Fig. 3b

Fig. 3 Post-operative clinical views (a) of case 2 at 24 months and b) post-operative standing radiograph at 24 months.

---

## Discussion

Metabolic bone diseases frequently result in skeletal deformities, especially in the legs, due to physal growth disturbances or defective mineralisation in children before puberty.<sup>2</sup> Among these disorders, hypophosphataemic rickets, hypophosphatasia, and renal osteodystrophy are the most frequent.<sup>2</sup>

The management of patients with multiapical bony deformities with established metabolic bone diseases is complex.<sup>1,5</sup> The deformities are either discrete and angular, or long-bowing (multiapical) deformities.<sup>1,2,5</sup> Angular deformities originate from or adjacent to the growth plate and often a single osteotomy is required to correct the deformity. Multiapical deformities usually result from bowing of the entire long bone. Frequently,

more than one osteotomy is needed to correct the deformity in order to produce a straight bone and avoid secondary iatrogenic deformities.<sup>2,5</sup>

Deformities in metabolic bone diseases occur in multiple limb segments. If the disease is not under metabolic control, deformities tend to recur after corrective osteotomies.<sup>2,5</sup> Operative correction of deformities in metabolic bone diseases tend to heal slowly.<sup>2,5</sup> Correction of all deformities with Ilizarov-type external fixators at one operation causes considerable discomfort. Sequential operations performed after treating one segment at a time increases the total time of correction and decreases a patient's compliance.

Osteotomy and stabilisation with Ilizarov-type external fixators allows gradual, controlled correction of a deformity with the advantages of high union and low infection rates because of the low energy involved in osteotomy and minimal intra-osseous fixation. The Ilizarov technique allows post-operative adjustments and prevents inequality of limb length. Ilizarov-type external fixators have some disadvantages such as pin-track infections, discomfort and bulkiness.<sup>3,5</sup> The technique chosen for stabilisation determines the healing time, complications, and patient comfort. Internal fixation provides high patient comfort but lacks corrective accuracy. External fixation allows per- and post-operative adjustment and thus high accuracy, but poor comfort.

FAN has a steep learning curve. Good quality intra-operative radiographs are a prerequisite for accuracy. The total treatment time is less than with other techniques. In these two cases, the technique did not create any limb length inequality.

No benefits in any form have been received or will be received from a commercial party related directly or indirectly to the subject of this article.

## References

1. **Smyth EHJ.** Windswept deformity. *J Bone Joint Surg [Br]* 1980;62-B:166-7. [\[Context Link\]](#)
2. **Mankin HJ.** Rickets, osteomalacia and renal osteodystrophy: an update. *Orthop Clin North Am* 1990;21:81-96. [\[Context Link\]](#)
3. **Paley D, Herzenberg JE, Bor N.** Fixator assisted nailing of femoral and tibial deformities. *Tech Orth* 1997;12:260-75. [\[Context Link\]](#)
4. **Paley D, Herzenberg JE, Tetsworth K, McKie J, Bhave A.** Deformity planning for frontal and sagittal plane corrective osteotomies. *Orthop Clin North Am* 1994;25:425-65. [Bibliographic Links](#) [\[Context Link\]](#)
5. **Stanitski DF.** Treatment of deformity secondary to metabolic bone disease with Ilizaroc technique. *Clin Orthop* 1994;301:38-41. [Ovid Full Text](#) [\[Context Link\]](#)



---

*Accession Number: 00004624-200409000-00028*

Copyright (c) 2000-2007 [Ovid Technologies, Inc.](#)

Version: rel10.5.1, SourceID 1.13281.2.21