



Van Nes rotationplasty in two patients with congenital femoral deficiency

Doğuştan femur yetersizliğinde uygulanan Van Nes rotasyonplastisi: İki olgu sunumu

Korhan OZKAN,¹ Mehmet KOCAOGLU,¹ Levent ERALP,¹ Fırat YAGMURLU²

¹Istanbul University, Istanbul Medical Faculty, Department of Orthopaedics and Traumatology;

²Ankara research and education hospital

Doğuştan femur yetersizliğinin spektrumu, basit hipoplaziden tam femur aplazisine kadar sıralanır. Genellikle tibia kısalığı ve fibular hemimeli ile birlikte görülür. Hastalığın bilinen bir genetik geçiş şekli yoktur. Bu anormallikler için iki temel tedavi yöntemi vardır: protektik replasman cerrahisi (Syme amputasyonu veya Van Nes rotasyonplastisini takiben protez kullanımı) ve uzatma rekonstrüksiyon cerrahisi. Bu yazıda doğuştan femur yetersizliği nedeniyle Van Nes rotasyonplastisi uygulanan biri 26 (erkek), diğeri yedi (kız) yaşında iki olgunun sonuçları sunuldu. İki olguda da tedavi süresi 1.5 ayda tamamlanarak protezle mobilizasyon sağlandı. Biri beş yıl, diğeri 1.5 yıl izlenen olgularda herhangi bir komplikasyon görülmedi. Özellikle çok kısa femoral segmenti olan hastalarda veya Paley sınıflandırmasına göre tip 3 femur yetersizliklerinde rotasyonplastisi ameliyatı fonksiyonel bir yürüme olanağı sağlamaktadır.

Anahtar sözcükler: Yapay ekstremiteler; çocuk; femur/anormallik/cerrahi; eklem protezi; diz eklemi/fizyoloji; bacak uzunluk eşitsizliği/cerrahi; osteotomi; rotasyon; tibia/cerrahi.

Congenital femoral deficiencies have a wide spectrum ranging from simple hypoplasia to complete femoral aplasia. They are often associated with congenital shortening of the tibia and fibular hemimelia. This anomaly has no known genetic transmission. There are two main treatment modalities for congenital femoral deficiency: prosthetic replacement surgery (Syme amputation or Van Nes rotationplasty followed by prosthetic fitting) and lengthening reconstruction surgery. In this report, we presented two patients (male, 26 years; girl, 7 years) with congenital femoral deficiency treated with Van Nes rotationplasty. In both cases, the treatment took 1.5 months, after which the patients were mobilized with prosthesis. No complications were encountered within a follow-up period of five years and 1.5 years, respectively. Rotationplasty enables an improved functional gait in patients with a very short femoral segment or Paley type 3 femoral deficiency.

Key words: Artificial limbs; child; femur/abnormalities/surgery; joint prosthesis; knee joint/physiology; leg length inequality/surgery; osteotomy; rotation; tibia/surgery.

Congenital femoral deficiency is rare a condition that is characterized with developmental defect of the femur. It is used in order to indicate deformities where the femur is shorter than normal and where there is no continuity between femoral neck and shaft. This syndrome which is often called as proximal femoral deficiency should rather be named as congenital femoral deficiency. This pathology has a wide spectrum ranging from simple hypoplasia to complete femoral aplasia.

Clinical appearance on the patients is evident; effected thigh is extremely short; the hip generally at flexion, external rotation and abduction. Flexion contracture in the knee is frequently observed. Clinical problems are femoral axis impairment, hip instability, coxa vara, limited hip motion due to muscular weakness and limp length discrepancy. In this pathology the anomalies are rarely limited to proximal femur. 45% of the cases have ipsilateral fibular hemimelia, shortening of tibia and additionally eci-

novalgus deformity of the foot. Lateral sequence of the foot can be missing as well. The etiology of the syndrome which can sometimes be seen on both sides is not known. A standard treatment protocol has not yet been developed to date for this pathology over which no consensus has been reached concerning its classification. Main treatment options are extremity lengthening (extension) prosthesis, ankle disarticulation and prosthesis, in addition to ankle disarticulation femoro-pelvic arthrodesis, rotation-plasty or lengthening reconstruction surgery. The most comprehensive classification including treatment has been conducted by Paley and friends (Table 1).

In Paley classification amputation stands out especially in type III displasias. In 1950 Van Nes described the technique in which foot and ankle could control the knee prosthesis by rotating the foot by 180° in patients with congenital absence of the femur.

Conducting hip joint fusion on patients with proximal focal femoral deficiency is a much disputed matter. Even though it is important concerning the patients who will undergo walking and lengthen-

ing reconstruction surgery in terms of stability, it nevertheless has an adverse effect that complicates the compatibility of prosthesis. It is advised that the knee fusion is generally conducted along with Syme amputation in order to achieve stability and in order for the deficiency to be placed right above the knee joint level.

In this study, two patients with congenital femoral deficiency treated with Van Nes rotation-plasty are presented.

Technique

There are two critical factors in deciding upon rotationplasty in the patients: (i) Hip joint stability. Since hip joint is not formed in Paley type 3 displasia, whether or not the patient can commence weight bearing upon his or her extremity following the reconstruction surgery can be assessed only by making the patient stand upon his or her short extremity (Table 2). (ii) The patients and their immediate family should be informed about the clinical appearance following the reconstruction surgery; previous cases should be presented if possible and the fact that this treatment is functional rather than cosmetic should be emphasized.

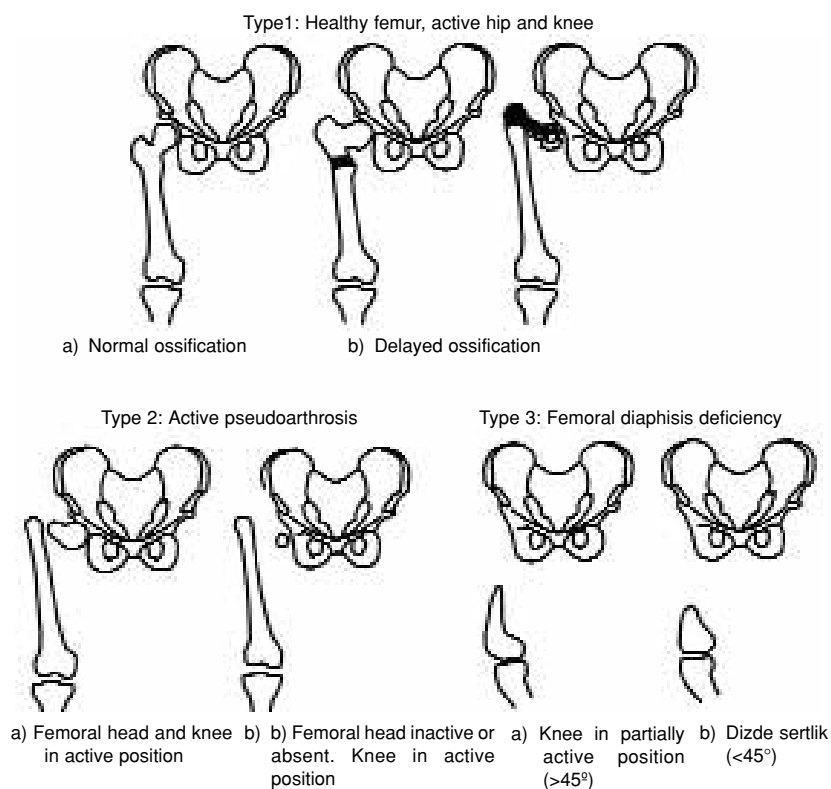


Figure 1. Paley classification

After patients are laid down in supine position under general anesthesia, an incision is performed at anteromedial of proximal thigh towards anterolateral at distal. Peroneal nerve is dissected for exploration. Tibia is marked in order to adjust the amount of rotation. After tibia and fibula are dissected, osteotomy is applied upon fibula up to 10 cm. Immediately afterwards, resection is conducted from tibia diaphysis according to femoral length.

Rotation axis is inclined towards lateral. The reason for this is that peroneal nerve is not stretched in lateral rotation. After the rotation is completed, segments are fixed by plate and screw. Whether or not the peroneal nerve is intact and stretched should be checked once more. Skin layers are sutured without closing the fascias (Table 3).

Case Presentation

Case 1– Complaining from difficulty in walking and extremity shortness, a patient, aged 26, has applied to our clinic. Orthopaedic evaluation

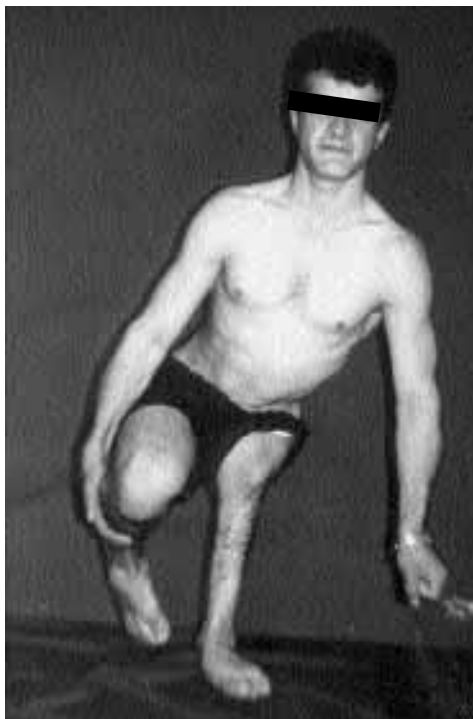

Figure 2. Whether or not the patient can commence weight bearing following the reconstruction surgery can be assessed only by making the patient stand upon his or her short extremity.

showed that right femur was measured as 415 mm, and right tibia 390 mm; where as left femur was measured as 130 mm and left tibia as 320 mm. In the radiological analysis, hip joint dysplasia was observed as stabile (Paley type 3). There was an extreme shortness and deformity in the femur; as well as dysplasia in femoral condyles. There was no other pathology that followed. The patient underwent Van Nes rotationplasty surgery in 1999. Following the surgery, ankle joint motion was started after applying a long leg circular plaster immobilization for 1.5 months.

The patient was mobilized with the help of long leg walking brace hinged over the knee within two months following the surgery. In the most recent control after five years, the patient's left ankle was at the same level as the opposite extremity knee. Ankle motion was 60 degrees at flexion extension arc. Hip was stabile, there was a 30° flexion contracture and it was able to make a 90° flexion. Lower right extremity was measured as 88 cm where as lower left extremity as 54 cm. The patient was content with his functional condition and dressed appearance (Table 4a).

Case 2 – Complaining from difficulty in walking and extremity shortness, a child patient, aged 7, has

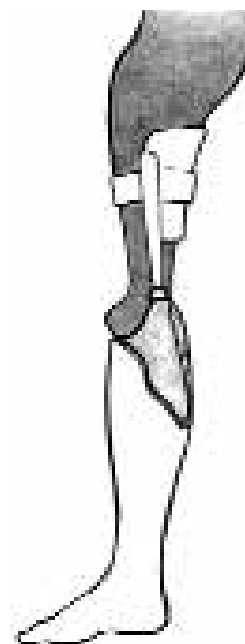


Figure 3. Rotationplasty applied for congenital femoral deficiency.

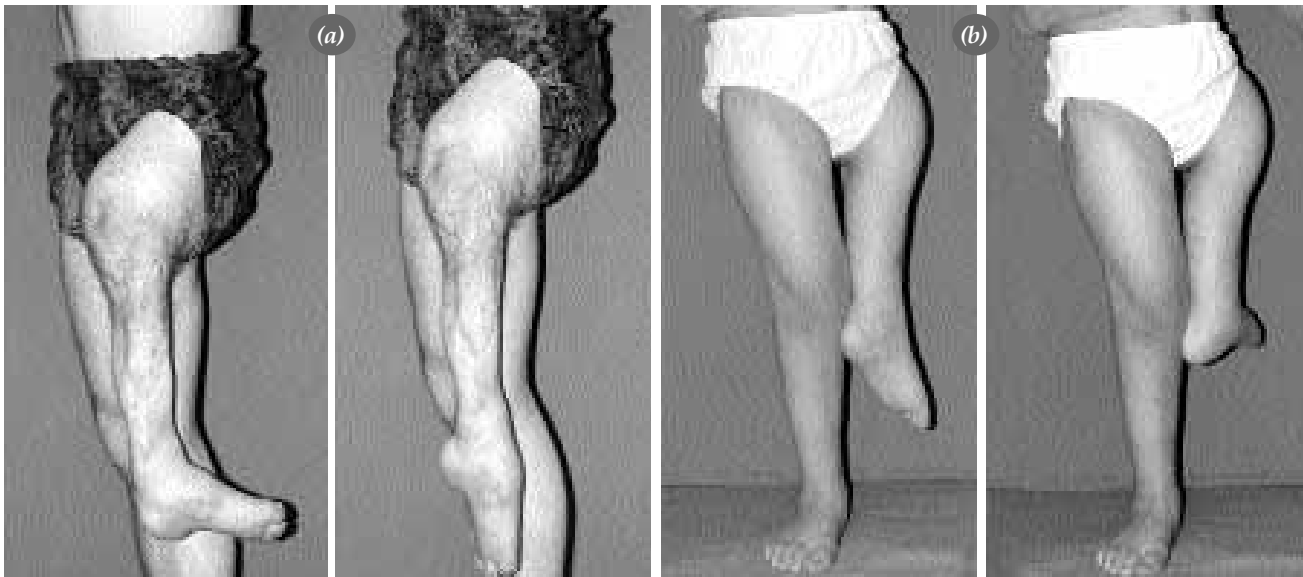

Figure 4. Rotationplasty performed on two patients with congenital femoral deficiency. (a) Case 1 and (b) Case 2 post-operation images.

applied to our clinic. In the radiological analysis, advanced dysplasia in proximal femur and dysplasia in femoral condyles were observed (Paley type 3b). Dysplasia on the patient's right hip and avascular necrosis on femoral head due to multiple operations she has had were determined. Close reduction has been conducted on the patient's right hip when she was a year old and after that open reduction was experimented twice. In the orthopaedic evaluation she has had before surgery, left femur was measured as 60 mm and left tibia as 282 mm; whereas right femur was measured as 260 mm and right tibia as 240 mm. There was a 158 mm of difference between the two extremities. She also had pelvic tilt. Her left hip flexion was 90° and external rotation was 30°. There was no contracture. Hip joint stability was assessed by requesting the patient to stand up on her extremity with congenital femoral deficiency. Since the patient was reported to stand upon the extremity, neither pelvis support osteotomy nor hip joint fusion was regarded as necessary.

The patient underwent Van Nes rotationplasty in 2003. Distal femur and proximal tibia epiphyses were preserved in order for normal growth potential to continue and knee arthrodesis was not performed. After 1.5 months of immobilization with long leg plaster, ankle joint exercises were started. In patient's most recent orthopaedic evaluation, right knee and left ankle were on the same level. There

was a 70° motion arc in the ankle. The patient was compatible with prosthesis within two months following the surgery and started walking without having problems (Table 4b).

Discussion

There are two main ways to follow, with regard to congenital femoral deficiency. These are namely prosthetic replacement surgery or lengthening

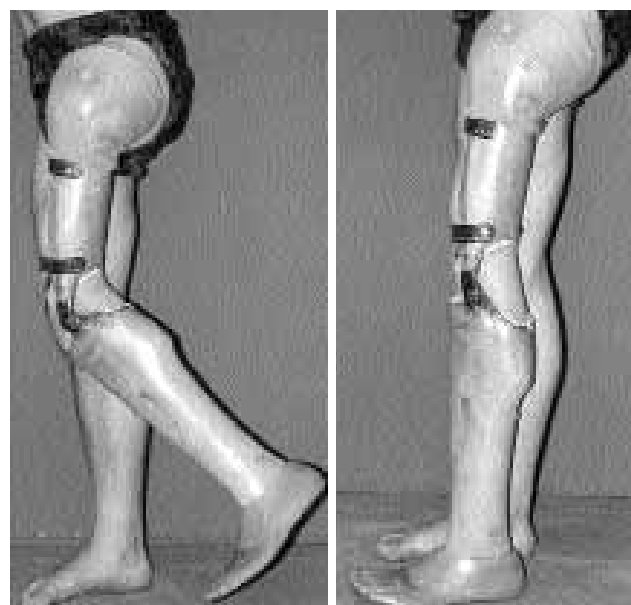


Figure 5. The ankle provides the prosthesis knee with motor and sensory control.

reconstruction surgery. Even though more functional results are obtained through lengthening reconstruction surgery, amount of shortness, condition of knee and hip joints can prevent the performance of this treatment. Another disadvantage of this treatment is that it takes a lot of time and effort. This treatment is reported to have adverse psychological effects and also leads to a negative childhood period. However, especially in type one cases this treatment should be preferred.

The purpose of Van Nes rotationplasty is replacing the knee joint with rotated feet by rendering the affected extremity to functional below-the-knee amputation. This operation is suggested for children above the age of four. In order for prosthesis to function efficiently, foot and ankle of the affected extremity should be normal and its post operation arc should measure at least 60°. In the presence of fibula, a stable hip and one sided involvement, better results have been reported.

Making a 180°, the ankle should be on the same level as the opposite knee. In both cases the ankles were on the same level as the knee of the opposite extremity.

Following this surgery, gastrosoleus muscle provides the ankle with primary motor force and functions as knee extensor. In both cases plasters were removed within 1.5 months following the surgery and a physical therapy program was initiated along with a physiotherapist. Since the objective was that the ankle should function as knee joint, extension, flexion and walking exercises were initiated while the ankle was in prosthesis. In both cases within two months following the surgery prosthesis was checked and proprioception was fully acquired.

The most crucial part of the operation is the dissection and protection of peroneal nerve. Otherwise, a probable peroneal paralysis that might follow the surgery would prevent active foot dorsiflexion, namely knee flexion.

Physical appearance that follows Van Nes rotationplasty is reported to be problematic and difficult to face for the patient and his or her immediate family. The patient and his or her immediate family should be informed prior to surgery about the condition that follows the surgery. Epps has suggested that

a prior case that had undergone this operation ought to be presented to the family. Some writers have suggested toe amputation in order to improve cosmetic appearance. We have not come across any visible complaints concerning the cosmetic appearance.

In a study where walking analyses in patients who have undergone Van Nes rotationplasty and Syme amputation, the Van Nes group has been reported to perform a much better prosthetic function. One of the most important advantages of rotationplasty, a much better proprioceptive control within the prosthesis is achieved due to the fact that sensory feedback of the ankle is preserved.

Following the rotationplasty the fact that the ankle is on the same level as the opposite knee is crucial in terms of both prosthetic appearance of the patient and walking mechanics.

In both cases where we have performed rotationplasty, treatment period has been completed within 1.5 months and mobilization has afterwards been achieved. No complication that necessitates a repeated surgery or repeated hospitalization has been reported. Especially the first case, due to mature age, has been able to perform daily activities. In both cases 180° rotation of the ankle has been achieved. While ankle remained at 180° rotation, the foot was passively brought up to external rotation. Prior to surgery, patients were made stand up on their extremities with femoral deficiency and their hip joint stability was evaluated. Since it was observed that they were able to stand up on their extremities, pelvis support osteotomy was not required for both cases.

One of the most crucial problems to be seen in rotationplasty is the risk of derotation. Following Van Nes rotationplasty, derotation may develop in the ankle in time. It can, moreover, necessitate a repeated rotationplasty. In order to prevent this, Gillespie and Torade and afterwards Krajchich, repositioned periarticular knee joint muscles by separating them from their insertio in order to obtain a traction force along a straight line on the rotated tibia through knee arthodesis. However, no further information on long term effects of this technique has been acquired. One of our cases has been monitored for five and the other for 1.5 years and no derotation has been reported. (Table 5).

In conclusion, we believe that rotationplasty surgery provides the patients with a more functional walking ability especially in patients with extreme femoral segments and in type 3 femoral deficiencies according to Paley classification. Although considered as an extremely comprehensive and aggressive operation, Van Nes rotationplasty does not lead to complications when performed in accordance with its rules (during surgery, rotation direction of the foot is towards the lateral. The aim of this approach is that peroneal nerve should not be stretched) and also provides the patients with possibility to return to their daily activities as soon as possible along with appropriate rehabilitation.

References

1. Kocaoğlu M. Reconstructive treatment modalities for congenital femoral deficiencies [Article in Turkish]. *Acta Orthop Traumatol Turc* 2000;34:535-46.
2. Koman LA, Meyer LC, Warren FH. Proximal femoral focal deficiency: a 50-year experience. *Dev Med Child Neurol* 1982; 24:344-55.
3. Paley D. Lengthening reconstruction surgery for congenital femoral deficiency. In: Herring JA, Birch JG, editors. *The child with a limb deficiency*. Rosemont IL: American Academy of Orthopaedic Surgeons; 1998. p. 113-5.
4. Kostuik JP, Gillespie R, Hall JE, Hubbard S. Van Nes rotational osteotomy for treatment of proximal femoral focal deficiency and congenital short femur. *J Bone Joint Surg [Am]* 1975;57:1039-46.
5. Brown KL. Resection, rotationplasty, and femoropelvic arthrodesis in severe congenital femoral deficiency. A report of the surgical technique and three cases. *J Bone Joint Surg [Am]* 2001;83:78-85.
6. Alman BA, Krajbich JI, Hubbard S. Proximal femoral focal deficiency: results of rotationplasty and Syme amputation. *J Bone Joint Surg [Am]* 1995;77:1876-82.
7. Beaty JH. Congenital anomalies of lower extremity. In: Canale ST, editor. *Campbell's operative orthopaedics*. 9th ed. St. Louis: Mosby-Year Book; 1998. p. 975-85.
8. Epps CH Jr. Proximal femoral focal deficiency. *J Bone Joint Surg [Am]* 1983;65:867-70.
9. Cammisa FP Jr, Glasser DB, Otis JC, Kroll MA, Lane JM, Healey JH. The Van Nes tibial rotationplasty. A functionally viable reconstructive procedure in children who have a tumor of the distal end of the femur. *J Bone Joint Surg [Am]* 1990;72:1541-7.
10. Fowler E, Zernicke R, Setoguchi Y, Oppenheim W. Energy expenditure during walking by children who have proximal femoral focal deficiency. *J Bone Joint Surg [Am]* 1996;78: 1857-62.
11. Kritter AE. Tibial rotation-plasty for proximal femoral focal deficiency. *J Bone Joint Surg [Am]* 1977;59:927-34.
12. Krajbich JI. Rotationplasty in the management of proximal femoral focal deficiency. In: Herring JA, Birch JG, editors. *The child with a limb deficiency*. Rosemont IL: American Academy of Orthopaedic Surgeons; 1998. p. 87-90.